Patient Name:	Holmes , Sherlock	**Gender:**	male
MRN:	0324234	**Age:**	65
Procedure Date:	2/4/2026		

Proceduralist(s): Emily Example, MD, Alan Synthetic, MD (Fellow)

Procedure Name: Bronchoscopy

Indications: Mediastinal adenopathy, Diagnostic

Medications: General Anesthesia, 2% Lidocaine, tracheobronchial tree 10 mL

Procedure Description: Procedure, risks, benefits, and alternatives were explained to the patient. All questions were answered and informed consent was documented as per institutional protocol. A history and physical were performed and updated in the preprocedure assessment record. Laboratory studies and radiographs were reviewed. A time-out was performed prior to the intervention. Following intravenous medications as per the record and topical anesthesia to the upper airway and tracheobronchial tree.The black bronchial tube 12.00-11.00 was introduced through the mouth and advanced to the tracheobronchial tree. The 0 degree 4.0mm rigid telescope was introduced through the mouth and advanced to the tracheobronchial tree. The Q180 slim video bronchoscope was introduced through the rigid bronchoscope (after telescope was removed) and advanced to the tracheobronchial tree. The T180 therapeutic video bronchoscope was introduced through the rigid bronchoscope (after telescope was removed) and advanced to the tracheobronchial tree. The patient tolerated the procedure well. The XPS 3000 microdebrider was introduced through the rigid bronchoscope (after telescope was removed) and advanced to the tracheobronchial tree. The ERBE APC VIO 300D unit was introduced through the rigid bronchoscope (after telescope was removed) and advanced to the tracheobronchial tree.

Findings: The vocal cords move normally with breathing. The subglottic space is normal. The trachea is of normal caliber proximally. The tracheobronchial tree was examined to at least the first subsegmental level. A mixed obstruction consisting of extrinsic compression and endoluminal tumor infiltration was found in the distal third of the trachea arising from the right lateral aspect and extending to involver the main carina and both mainstem bronchi for a distance of about a centimeter. The airway lumen is about 75% occluded in the lower trachea. The mass involving the main carina was large and endobronchial, friable, infiltrative and submucosal. The carinal mass was partially resected using the electrocautery snare and sent to pathology for review. This resulted in 60% recanalization of the distal airway at the level of the main carina. Endobronchial biopsies were performed in the lower trachea and at the carina using a cup forceps and sent for histopathology examination. Five samples were obtained. The microdebrider was then used to resect additional tumor in the lower trachea and the airway was partially recanalized to about 50% of normal. Tumor ablation was performed in the trachea, at the carina, in the left mainstem bronchus of the lung and in the right mainstem bronchus of the lung using an Argon Plasma Coagulation (APC). The post-procedure lumen size was 70% of normal. Given the residual obstruction and the extent of endoluminal disease, we elected to place a silicone Y stent to maintain airway patency pending treatment. A 14-10-10mm Novatec stent was selected and customized to 6 cm (tracheal length) and 1cm in each mainstem limb. The silicone stent was placed in the trachea, at the carina, in the left mainstem bronchus of the lung and in the right mainstem bronchus of the lung using a dedicated stent deployer under direct vision. The post-stent lumen size was 90% of normal. The stent was not blocking orifices of any other airways. The final stent placement was in the desired location.

Complications: No immediate complications

Estimated Blood Loss: Less than 5 cc.

Post Procedure Diagnosis: - Mediastinal adenopathy

Recommendation: - Technically successful rigid bronchoscopy with endobronchial biopsies, tumor debulking and stent placement. The patient has remained stable and has been transferred in good condition to the post bronchoscopy recovery area, where patient will be observed until discharge criteria is met. Preliminary findings have been discussed with the patient and follow-up with the requesting service for the final pathological result has been recommended.

Patient Name:	Holmes , Sherlock	**Gender:**	male
MRN:	0324234	**Age:**	65
Procedure Date:	2/4/2026		

- Await pathology results.

Attending Participation: I was present and participated during the entire procedure, including non-key portions.

Add'l Images:

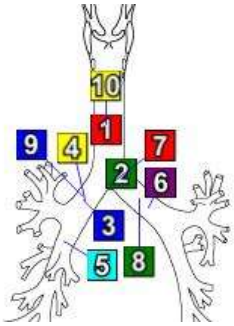

Tracheobronchial Tree

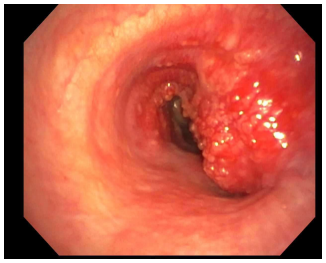

1 Trachea : Mass, Endobronchial biopsy, Extrinsic compression, Laser/Plasma Ablation

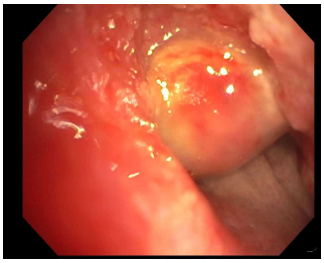

2 Carina : Endobronchial biopsy, Excision, Laser/Plasma Ablation

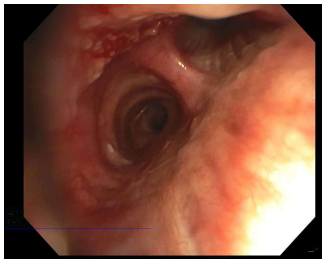

3 Right mainstem bronchus : Mass

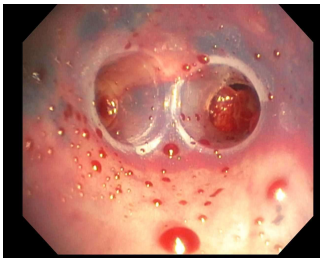

7 Carina : Stent placement

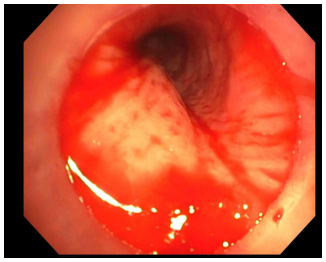

8 Left mainstem bronchus : Stent placement

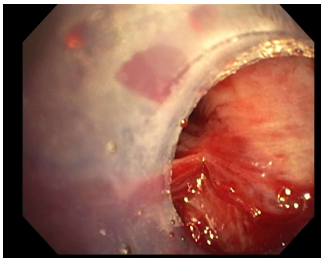

9 Right mainstem bronchus : Stent placement

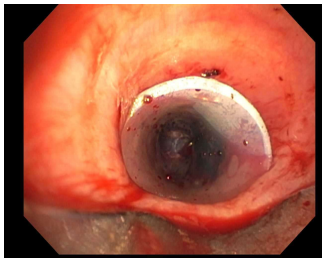

10 Trachea : Stent placement

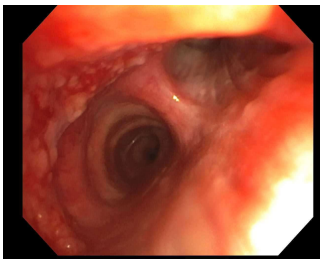

4 Right mainstem bronchus

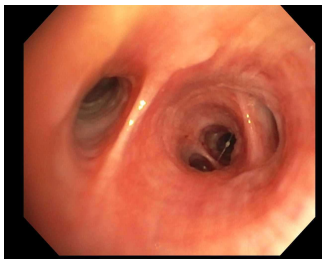

5 Bronchus intermedius

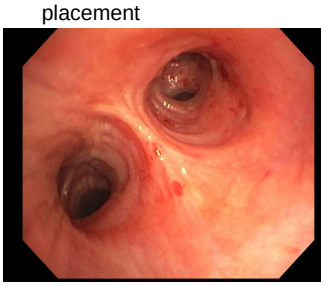

6 Left mainstem bronchus

Emily Example, MD

Emily Example, MD
2/4/2026 4:48:02 PM
This report has been signed electronically.

Number of Addenda: 0